
Annals of Clinical and Analytical Medicine

The Use of Three-Dimensional Ultrasound in the Antenatal Care

*Hadi Mohammad H Al Yami (1) *, Waleed Ali Abdullallah Alghamdi (2), Ali Ahmad Ali Alsagoor (3), Mahdi Saleh Alrabeai (4), Hamad Almuneef (5), Mohammed Hamad Hadi Alyami (6), Ali Saleh bin Abdullah Almunyif (7), Ali Nasser Nasser Al-Nasser (8), Ibrahim Ali Ibrahim Alzahrani (9), Saleh Nasser Almansour (10)*

- (1) *Radiological Specialist, Najran Specialist Dental Center, Najran, Saudi Arabia.*
(2) *Radiology Technician, Najran Armed Forces Hospital, Najran, Saudi Arabia.*
(3) *Medical Imaging Technologist, Najran General Hospital, Najran, Saudi Arabia.*
(4) *Master of Medical imaging, Wadi Riman Health Center, Najran, Saudi Arabia.*
(5) *Pharmacy, Najran General Hospital, Najran, Saudi Arabia.*
(6) *Staff Nurse, Najran General Hospital, Najran, Saudi Arabia.*
(7) *Radiology Technician, Najran Specialty Dental Center, Najran, Saudi Arabia.*
(8) *Emergency Medicine Specialist, Al-Qabil Health Center, Najran, Saudi Arabia.*
(9) *Assistant Specialist-Health Administration, Irada & Mental Health Complex In Jeddah, Saudi Arabia.*
(10) *Health Informatics, Najran Specialist Dental Center, Najran, Saudi Arabia.*

Received 17/11/2022; revised 5/12/2022; accepted 18/12/2022

**Corresponding author*

Abstract

Introduction: There is a current belief that 3D ultrasound is a time-saving technique that can play an important role the future. However, it is not obvious what the clinical significance of the additional data provided by 3D ultrasound imaging. This review aimed to evaluate the evidence assessing the accuracy of 3D ultrasound, in the antenatal care in different populations at different pregnancy trimesters.

Methods: We performed a systematic literature search of the MEDLINE and EMBASE databases. The detected citations from several databases were combined and duplicate articles were excluded. The titles and abstracts of all selected publications were inspected for relevance based on the following inclusion criteria: Members of these populations had already passed the primary care stage, were clinically suspected or confirmed as having a fetal deformities and had been referred for further evaluation ('high-risk population study').

Results: The literature search yielded 45 citations. There was no disagreement between the two assessors regarding inclusion of studies. The initial screening by title identified 33 abstracts that were potentially relevant. In total 27 studies met all the inclusion criteria as well as the internal and external validity criteria. Variability in the design and results of the selected studies were based on the type of the included communities. Among included studies, 21 studies consisted of unselected population-based groups of pregnant women ('low-risk population study') and six studies dealt with a population with a positive family history and/or pre-screened fetuses who were suspected to have anomalies.

Conclusions: This review confirms that studies reporting on the accuracy of 2D ultrasound in detecting cleft lip and/or palate in low-risk populations demonstrate a wide variety in diagnostic accuracy.

Keywords: Ultrasound, Sonography, Pregnancy, Anomalies, Cleft lip, Palate.

Introduction

The prenatal screening of congenital anomalies becomes a major research area in obstetrics. Ultrasound has been used as an important tool for prenatal detection of congenital anomalies including facial clefting [1]. Facial clefts resulted from failed fusion of jaw arch maxillofacial and nasal processes in the embryogenesis stage. The cleft lip plus or minus cleft palate are the most common facial clefts, which could occur as isolated anomaly or associated with other global anomalies and syndromes [2]. Cleft lip and palate incidence has reported to reach 2.19/ 1000 live births in central province of Saudi Arabia, which is a higher incidence when compared to other countries such UK (incidence rate was 182/1000 live births) [3, 4].

When using ultrasound, the detection rate of these clefts differed greatly according to the skills of the operator and the design of study. It ranges from as low as 13% in a prospective study conducted by Stoll et al., [5] to as high as 90% in a retrospective study conducted by Benacerraf et al. [6] Proper prenatal screening associated with early detection of facial clefts, especially in low risk population, can improve the management plan. Recently, the three-dimensional (3D) ultrasound imaging techniques have introduced to the prenatal screening methods [7]. The benefits of using 3D ultrasound imaging include the provision of depth and volume, which exploring more details than those available in two-dimensional (2D) ultrasound imaging [8]. There is a current belief that 3D ultrasound is a time-saving technique that can play an important role the future. However, it is not obvious what the clinical significance of the additional data provided by 3D ultrasound imaging. Although, there is a lack of robust evidence from a prospective cohort studies that supporting using of 3D ultrasound, it becomes widely used in clinical practice of obstetrics [7]. The main problem occurs when using 3D ultrasound is the deviation from the initial plane, which can reduce the quality of the images. In addition to problem of acoustic shadowing, that may also occur

in 2D ultrasound [9]. Recently, it becomes possible to update the 3D image at rate of 24/second which leads

to live view of the 3D volumes or what is known as 4D ultrasound imaging [10]. This review aimed to evaluate the evidence assessing the accuracy of 3D ultrasound, in the antenatal care in different populations at different pregnancy trimesters.

Methods

We performed a systematic literature search of the MEDLINE and EMBASE databases. The detected citations from several databases were combined and duplicate articles were excluded. The titles and abstracts of all selected publications were inspected for relevance based on the following inclusion criteria: Members of these populations had already passed the primary care stage, were clinically suspected or confirmed as having a fetal deformities and had been referred for further evaluation ('high-risk population study'). Targeted population is pregnant women in their second trimester (14-28 weeks' gestation) of pregnancy; of the internal and external validity. The main detected anomalies were cleft lip (CL), cleft palate (CP) and cleft lip and palate (CL+CP). The results of the included studies were summarized in the following section.

Results and discussion

The literature search yielded 45 citations. There was no disagreement between the two assessors regarding inclusion of studies. The initial screening by title identified 33 abstracts that were potentially relevant. In total 27 studies met all the inclusion criteria as well as the internal and external validity criteria [11-37]. Variability in the design and results of the selected studies were based on the type of the included communities. Among included studies, 21 studies consisted of unselected population-based groups of pregnant women ('low-risk population study') and six

studies dealt with a population with a positive family history and/or pre-screened fetuses who were suspected to have anomalies [12]. The retrospective cohort studies reported a large variety in the diagnostic accuracy of 2D ultrasound, with detection rates ranging from 0% to 70% for prenatal detection of all types of cleft, 33% to 88% for prenatal detection of CL \pm P and 0% to 22% for detection of CP. In prospective cohort studies, detection ranged from 9% to 73% for prenatal detection of all types of cleft, 9% to 100% for prenatal detection of CL \pm P and 0% to 7% for detection of CP. In several studies, all prenatal diagnosis of CL \pm P was confirmed following delivery or post-mortem, indicating no false positive diagnoses [13-18].

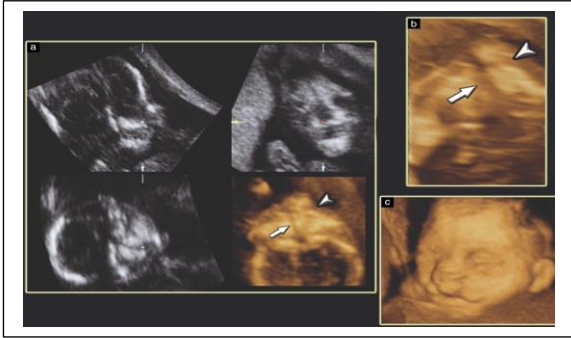
During prenatal period, 127 cleft babies were born, of which 29 cases had CL \pm P predicted prenatally, resulting in a detection rate of 23%. None of the 98 cases of CP was diagnosed prenatally. The prenatal detection rate of orofacial clefts increased significantly over time (14% in 1992-1996 and 30% in 1996- P = 0.03). The other recent prospective cohort study, also showed a significant increase in prenatal detection with time (34% in 1987-1996 and 58% in 1996- P = 0.03). CL \pm P was detected in 35 of the 77 (45%) cases with CL \pm P on delivery. Of these CL \pm P cases, 24 (31%) were detected during routine second-trimester ultrasound exam [14]. Not one of the 24 cases of CP was diagnosed prenatally. Of the six selected high-risk population studies 29 -34, three were retrospective 29 -31 and three were prospective 32 -34 [15]. In the retrospective study a detection rate of 41% (39/96) for unilateral clefts and 44% (8/18) for bilateral cases.

All 3D ultrasound studies showed a detection rate of 100% with the exception of a study that reported a detection rate of 87% (27/31) for unilateral clefts and 66% (2/3) for bilateral clefts 16-19. Three studies assessed the detection rate of anomalies, finding rates of 88% (37/42) in unilateral anomalies, 90% (18/20) in bilateral anomalies 31 and 90% (37/41) 32 and 86% (19/22) of all anomalies on 3D imaging 33 [20-22]. Two studies assessed the detection rate for CP, which varied from 0% (0/95) on two-dimensional imaging 30 to 89% (8/9) on three-dimensional (3D) imaging [23-25]. Two studies showed a significant increase in the

detection rate of 3D ultrasound in comparison with 2D ultrasound [26-28]. In unobstructed view of the structures of the palate, nasal cavity and orbits could then be seen by scrolling the view bar along the length of the palate. In the case of a normal intact palate, a distinct line could be seen to separate the nasal and oral cavities along the length of the hard palate [29]. A palatal cleft was characterized by absence of the palatal echo with continuity between the oral and nasal cavities and (if large) herniation of the tongue into the nasal cavity. The soft palate could not be confidently identified and was not included in our protocol [23]. Thus, each baby could have a maximum of five component clefts. One hundred antenatal diagnoses were available for comparison with postnatal outcomes. The postnatal examination revealed cases of isolated clefting of the soft palate but, as these defects were not included in our protocol, only clefts of the hard palate were included in this analysis [28]. The detection rates for clefts of the secondary palate using 2D ultrasound have remained low, even in those patients in whom a cleft lip has been detected [30]. The accuracy of antenatal diagnosis is therefore particularly helpful in preparing parents for the birth of their child with regard to both practicalities and prognosis. The presence of a limb across the face obstructed views of the lips and alveolus in the frontal view, and caused shadowing of the palate in the 3D-RF view; this required either a change in maternal position or, if necessary, a different visit. 3D-RF views were obtained quickly and easily, usually within 2-3 min following acquisition of a frontal facial view [31].

This is problematic because secondary palatal involvement can alter the long-term prognosis for the child, being commonly associated with difficulties in speech, hearing and (following surgery) mid-face protrusion. The objective of this study was to investigate the application of a relatively new technique -the three-dimensional (3D) reverse-face (RF) (3D-RF) view 11 -to examine particularly the foetal palate, but also the lips and alveolar ridge, following the finding of an isolated facial cleft upon an ultrasound scan. To avoid confusion, we differentiate between cleft lip, alveolus and secondary palate according to the classification of Kernohan. The prenatal detection of orofacial clefting is achieved

almost exclusively by ultrasound [32]. Further movement of the view bar through the face to identify the palate usually resulted in a severely shadowed image which was diagnostically unhelpful and may be misleading (Figure 3b-d).



This provided an unobstructed view of the palatal area, nasal cavity and orbits. It is important that a true coronal plane is obtained [33]. The surface-rendered mode, in our experience, provided optimal visualization of the hard palate, although the gradient light algorithm also provided excellent views, especially of the bony palate and nasal cavity (Figure 5). This was probably due to the fact that the soft tissues of the velum do not provide sufficient reflections, although another factor is that as the velum hangs vertically down from the back of the hard palate, the plane of the soft palate is not at right angles in the coronal section. The diagnosis of facial cleft made in all eight cases by the RF view is illustrated here by a brief description of each case [34].

The RF view overcame this problem. In normal cases, the intact palate was then seen as a distinct line separating the nasal from the oral cavities. The hard palate could be clearly seen throughout its length, the only exception being when a limb in front of the face caused significant shadowing. This was usually only a temporary problem. Visualization of the hard palate, however, was not affected by umbilical cord or placenta. Degrees of obliquity of more than a three-quarter profile were unsuitable for obtaining a good RF view. We did not confidently identify the soft palate [26]. The diagnosis and antenatal categorization of facial cleft was made in all eight cases by the RF view and these were all compared with detailed assessment after birth. The technique was rapid; obtaining the frontal view of the face to completion of

visualization of the palate took 2 or 3 min. In all cases (except Case 8) the stored 3D volume was analysed antenatally. In seven cases the categorization was made before the baby was born; in Case 8 the analysis of the 3D volume was made after the child was born but the analysis by one of us (S. Case 1 was referred at 31 weeks because a scan 3 weeks previously at a tertiary center had diagnosed bilateral CL with major bilateral clefting of the alveolus. These findings were confirmed. The RF view demonstrated a large defect in the primary and secondary palates. The edges of the cleft in the secondary palate were obscured by the tongue, which was partially elevated into the nasal cavity. The baby was born by spontaneous Case 2 was referred at 29 weeks because a scan 5 weeks previously at a tertiary center had diagnosed left-sided CLA with deviation of the nasal septum. The RF view identified a narrow cleft of the secondary palate. The baby was delivered spontaneously at 39 weeks and had UCLP. The CLA was repaired 3 months after birth and the CP 2 months after this. Case 3 was referred at 25 weeks [29].

The local tertiary hospital diagnosed a left-sided CLA. This was confirmed; the defect in the alveolar ridge measured 15.4 mm. The RF view showed a narrow cleft of the secondary palate. The baby was delivered spontaneously at 40 weeks and weighed 3.6 kg. A left-sided CLA and CP were present. The diagnosis was confirmed and at this time sonography could not exclude a right-sided CL. The RF view revealed a narrow clefting of the hard palate. The baby was delivered spontaneously at 37 weeks and weighed 3.3 kg. A bilateral CL was present and there was also a defect in the secondary palate. The CL was repaired at 3 months and the palate was successfully closed at 6 months [35]. Case 5 was referred at 25 weeks because a CL had been diagnosed on routine scanning at a district hospital at 21 weeks. The defect in the alveolar ridge measured 0.55 mm. The RF view demonstrated a large cleft of the secondary palate. The baby girl was delivered by Cesarean section at 41 weeks and weighed 3.6 kg. A right-sided CL with a defect in the hard palate was confirmed. The cleft in the secondary palate was repaired 3 months after birth in a one/two-stage procedure. The lesion in the lip was thought to reach the nostril but did not distort the nasal structure. The RF view identified a large defect in the secondary

palate. There was a large herniation of the fetal tongue through the defect into the nasal cavity, obscuring the margins of the defect [17]. The baby was delivered spontaneously at 40 weeks, and weighed 3.96 kg. A left-sided CLA with a large palatal defect was present. A right-sided CL was identified and there was a defect in the alveolar ridge measuring 12 mm. The RF view identified a large defect in the secondary palate. The baby was delivered spontaneously at 39 weeks. The ultrasound findings were confirmed. A partial closure of the palatal defect was performed at 6 months and complete closure of the palate and alveolus will be completed at 6-7 years of age. A unilateral left-sided CL and alveolar ridge was noted on both 2D and 3D examinations. The child was noted to have a complete CL with a fissure in the alveolus. The hard palate was intact but there was an unpredicted cleft of the soft palate. There was a tiny 'notch' in the palpable posterior border of the hard palate. The baby therefore had an incomplete cleft of the primary palate and an incomplete cleft of the secondary palate. Without knowledge of the postnatal findings analysis of the stored volume diagnosed left sided clefting of the lip and alveolar ridge (Figure 13a) and an intact hard palate. T

he cleft in the soft palate was not identified although subsequent analysis after knowledge of the postnatal findings did suggest a cleft of the velum [35]. However, in early studies, inclusion of the face in the examination protocol was not always mandatory, nor was the examination protocol itself fully adequate when compared with present standards of fetal facial examination. These numbers reflect better examination protocols and improvements in sonographic equipment. Prenatal recognition of facial clefts will alert the physician to perform chromosomal analysis and look for an associated syndrome or non-syndromic polymalformative state [36]. Precise characterization of the extent of clefting permits counselling of the parents and planning of the birth in an appropriate tertiary center with adequate neonatal resources. Early diagnosis will allow the parents to discuss with the surgeon the possibilities of corrective surgery and, in more severe cases, termination of pregnancy. In cases of complex clefting, the baby will require repeated surgical procedures, prolonged dental care and speech therapy, and may endure considerable

medical, psychological and social problems 13 -15 . As previously reported 18 , the study population consisted mainly of a local population which was offered routine screening during pregnancy. CL, uni- or bilateral, are analyzed in Table 3, and depicted in Figure 3. Anomalies encountered when a cleft of the alveolus, uni- or bilateral, was present, are depicted in Table 4 and Figure 4. Anomalies encountered in the presence of a CSP are depicted in Table 5 and Figure 5. As shown in Figure 6, the presence of a midline echo on the mid-sagittal view, immediately above the tongue, did not necessarily indicate palate integrity. To our knowledge, two clefts were missed at sonography. As it was not possible to obtain postnatal information for all fetuses scanned in our center or referring centers, this study cannot address the false-negative rate of cleft detection [37].

Conclusions

Fetuses with orofacial clefts identified by ultrasound, however, represent a different group from cleft neonates since a considerable number of cases never reach term due to potentially lethal associated malformations leading to termination of pregnancy. This review confirms that studies reporting on the accuracy of 2D ultrasound in detecting cleft lip and/or palate in low-risk populations demonstrate a wide variety in diagnostic accuracy.

Conflict of interests

The authors declared no conflict of interests.

References

1. Chmait, R., et al., Prenatal detection of associated anomalies in fetuses diagnosed with cleft lip with or without cleft palate in utero. *Ultrasound in obstetrics & gynecology*, 2006. 27(2): p. 173-176.
2. Jones, M., Facial clefting: etiology and developmental pathogenesis. *Clinics in plastic surgery*, 1993. 20(4): p. 599-606.
3. Borkar, A., A. Mathur, and S. Mahalaxmivala, Epidemiology of facial clefts in the

central province of Saudi Arabia. *British journal of plastic surgery*, 1993. 46(8): p. 673-675.

4. Turner, G. and P. Twining, The facial profile in the diagnosis of fetal abnormalities. *Clinical radiology*, 1993. 47(6): p. 389-395.

5. Stoll, C., et al., Evaluation of prenatal diagnosis by a registry of congenital anomalies. *Prenatal diagnosis*, 1992. 12(4): p. 263-270.

6. Benacerraf, B.R. and J.B. Mulliken, Fetal cleft lip and palate: sonographic diagnosis and postnatal outcome. *Plastic and reconstructive surgery*, 1993. 92(6): p. 1045-1051.

7. Dückelmann, A.M. and K.D. Kalache, Three-dimensional ultrasound in evaluating the fetus. *Prenatal diagnosis*, 2010. 30(7): p. 631-638.

8. DeVore, G., et al., Spatio-temporal image correlation (STIC): new technology for evaluation of the fetal heart. *Ultrasound in obstetrics & gynecology*, 2003. 22(4): p. 380-387.

9. Nelson, T.R. and T.T. Elvins, Visualization of 3D ultrasound data. *IEEE Computer Graphics and Applications*, 1993. 13(6): p. 50-57.

10. Maeda, K. and A. Kurjak, The safe use of diagnostic ultrasound in obstetrics and gynecology. *Donald School Journal of Ultrasound in Obstetrics and Gynecology*, 2012. 6(3): p. 313-317.

11. Äumler, M., Faure, J.-M., Bigorre † ‡, M., Äumler-Patris, C., Boulot, P., Demattei, C. and Captier, G. Accuracy of prenatal three-dimensional ultrasound in the diagnosis of cleft hard palate when cleft lip is present. (2011) *Ultrasound Obstet Gynecol.* 38(4); 440-444.

12. Roelfsema, N., Hop, W., Van Adrichem, L. and Wladimiroff, J. Craniofacial variability index determined by three-dimensional ultrasound in isolated vs. syndromal fetal cleft lip/palate. (2007) *Ultrasound Obstet Gynecol.* 29(3); 265-270.

13. Sommerlad, M., Patel, N., Vijayalakshmi, B., Morris, P., Hall, P., Ahmad, T., Campbell, S. and Lees, C. Detection of lip, alveolar ridge and hard palate abnormalities using two-dimensional ultrasound enhanced with the three-dimensional reverse-face view. (2010) *Ultrasound Obstet Gynecol.* 36(5); 596-600.

14. Clementi, Maurizio., Tenconi, Romano., Bianchi, Fabrizio. and Stoll, Claude. Evaluation of prenatal diagnosis of cleft lip with or without cleft

palate and cleft palate by ultrasound: experience from 20 European registries. ()

15. Benacerraf, B., Sadow, P., Barnewolt § ¶, C., Estroff, J. and Benson, C. Cleft of the secondary palate without cleft lip diagnosed with three-dimensional ultrasound and magnetic resonance imaging in a fetus with Fryns' syndrome. (2006) *Ultrasound Obstet Gynecol.* 27(5); 566-570.

16. Merz, Eberhard. and Welter, C. 2D and 3D Ultrasound in the Evaluation of Normal and Abnormal Fetal Anatomy in the Second and Third Trimesters in a Level III Center. (2005) *Ultraschall in Med.* 26(01); 9-16.

17. Chmait, R., Pretorius, D., Moore, T., Hull, A., James, G., Nelson, T. and Jones, M. Prenatal detection of associated anomalies in fetuses diagnosed with cleft lip with or without cleft palate in utero. (2006) *Ultrasound Obstet Gynecol.* 27(2); 173-176.

18. Maarse, W., Berg É †, S., Pistorius, L., Van Barneveld, T., Kon, M., Breugem, C. and Mink Van Der Molen, A. Diagnostic accuracy of transabdominal ultrasound in detecting prenatal cleft lip and palate: a systematic review. (2010) *Ultrasound Obstet Gynecol.* 35(4); 495-502.

19. Cash, C., Set, P. and Coleman, N. The accuracy of antenatal ultrasound in the detection of facial clefts in a low-risk screening population. ()

20. Wayne, C. and Thilaganathan, B. Sensitivity and accuracy of routine antenatal ultrasound screening for isolated facial clefts. ()

21. Campbell, S. and Lees, C. The three-dimensional reverse face (3D RF) view for the diagnosis of cleft palate. (2003) *Ultrasound Obstet Gynecol.* 22(5); 552-554.

22. Martinez-Ten, P., Adiego, B., Illescas, T., Bermejo, C., Wong, A., Sepulveda, W. and Sepulveda, . First-trimester diagnosis of cleft lip and palate using three-dimensional ultrasound. (2012) *Ultrasound Obstet Gynecol.* 40(1); 40-46.

23. Faure, Jean-Michel., Bäumlér, Marcel., Bigorre, Michèle., Captier, Guillaume., Boulot, Pierre. and Faure, J.-M. Prenatal diagnosis of an isolated incomplete V-shaped cleft palate using a new three-dimensional ultrasound technique investigation. (2007) *Surg Radiol Anat.* 29(8); 695-698.

24. Mittermayer, C., Blaicher, W., Brugger, P., Bernaschek, G., Lee, A., Mittermayer, Md., Diagnostik, Pränatale., Kieferspalte, Lippenspalte.,

Ultraschall, Zweidimensional. and Ultraschall, Dreidimensional. Foetal Facial Clefts: Prenatal Evaluation of Lip and Primary Palate by 2D and 3D Ultrasound. (2004) *Ultraschall in Med.* 25(02); 120-125.

25. Zajicek, Michal., Achiron, Reuven., Weisz, Boaz., Shrim, Alon. and Gindes, Liat. Sonographic assessment of fetal secondary palate between 12 and 16 weeks of gestation using three-dimensional ultrasound. (2013) *Prenat Diagn.* 33(13); 1256-1259.

26. Platt, Lawrence., Devore, Gregory. and Pretorius, Dolores. Improving Cleft Palate/Cleft Lip Antenatal Diagnosis by 3-Dimensional Sonography The "Flipped Face" View. ()

27. and Kalache, Karim. Three-dimensional ultrasound in evaluating the fetus. (2010) *Prenat. Diagn.* 30(7); 631-638.

28. Johnson, Donna., Pretorius, Dolores., Budorick, Nancy., Jones, Marilyn., Lou, Karen., James, Gina. and Nelson, Thomas. . ()

29. Tonni, Gabriele., Centini, Giovanni., Rosignoli, Lucia. and Siena, . Prenatal screening for fetal face and clefting in a prospective study on low-risk population: Can 3- and 4-dimensional ultrasound enhance visualization and detection rate?. (2005) *Oral Surgery, Oral Medicine, Oral Pathology, Oral Radiology, and Endodontology.* 100(4); 420-426.

30. Xu, Hui-Xiong., Zhang, Qing-Ping., Lu, Ming-De. and Xiao, Xian-Tao. Comparison of two-dimensional and three-dimensional sonography in evaluating fetal malformations. (2002) *J. Clin. Ultrasound.* 30(9); 515-525.

31. Faure, J., Captier, G., Äumler, M. and Boulot, P. Sonographic assessment of normal fetal palate using three-dimensional imaging: a new technique. (2007) *Ultrasound Obstet Gynecol.* 29(2); 159-165.

32. Faure, J.-M., Äumler, M., Boulot, P., Bigorre, M. and Captier, G. Prenatal assessment of the normal fetal soft palate by three-dimensional ultrasound examination: is there an objective technique?. (2008) *Ultrasound Obstet Gynecol.* 31(6); 652-656.

33. Pretorius1, Dolores., House1, Michael., Nelson1, Thomas., Hollenbach2, Kathryn. and Pretorius, D. Evaluation of normal and abnormal lips in fetuses: comparison between three- and two-dimensional sonography.. (1995) *American Journal of Roentgenology.* 165(5); 1233-1237.

34. Wang, L., Leung, K. and Tang, Mary. Prenatal evaluation of facial clefts by three-dimensional extended imaging. (2007) *Prenat. Diagn.* 27(8); 722-729.

35. Roelfsema, N., Hop, W. and Wladimiroff, J. Three-dimensional sonographic determination of normal fetal mandibular and maxillary size during the second half of pregnancy. (2006) *Ultrasound Obstet Gynecol.* 28(7); 950-957.

36. Three-dimensional sonography of unilateral Tessier number 7 cleft in a mid-trimester fetus. (2005) *Ultrasound Obstet Gynecol.* 26(1); 98-99.

37. Gindes, Liat., Weissmann-Brenner, Alina., Zajicek, Michal., Weisz, Boaz., Shrim, Alon., Geffen, Keren., Mendes, David., Kuint, Jaacov., Berkenstadt, Michal. and Achiron, Reuven. Three-dimensional ultrasound demonstration of the fetal palate in high-risk patients: the accuracy of prenatal visualization. (2013) *Prenat Diagn.* 33(5); 436-441.

